

PARMENTER AUTOPSY

Wound No. 1, Bullet No. 5 (Exh. 25) extended three inches below nipple, left course 2-1/2 inches. Entrance 1 inch to the right of the middle line. Flesh wound not cause of death.

WOUND NO. 2, BULLET NO. 6 (EXH. 24) Entrance in the right back 3 inches from the middle line, 4-1/2 inches above crest of the hip bone.

COURSE was from behind, forward and to the left in about the horizontal plane diagonally of the body; surgical incision in front of the body.

THIS WOUND caused internal bleeding, which caused death.

Dr. Hunting says it is the bullet with the "X" on it, being bullet No. 6 and Exh. 24.

BERARDELLI AUTOPSYWOUND NO. 1, BULLET NO. 2, (EXH 19)

Left upper arm into chest cavity between second and third ribs, making small hole in the top of the left lung; stopped in chest cavity under the left third rib. "There I found bullet No. 2."

COURSE 45 degrees to the right of the sejital (Parpendicular) plane of the body 20 degrees below the horizontal.

WOUND NO. 2, BULLET NO. 1, (EXH. 20)

6-1/2 inches to the left of the middle line on the back, 2 inches below the level of the arm-pit in the left pectoral muscles. This bullet skirted the chest in a semi-circular course about level. Bullet No. 1 found in the left pectoral muscles.

WOUND NO. 3, BULLET NO. 4, (EXH. 21)

Left side of the back, 6 inches to the left of the middle line 1-1/2 inches below the crest of the hip bone, causing detachment of a piece of the large intestine and a tiny wound of the wall of the left belly. Bullet No. 4 was found in the rectus muscle.

DIRECTION OF THE BULLET was from behind, forward toward the middle line and a little upward.

WOUND NO. 4, BULLET NO. 3, (EXH. 18)

On the right side of the back near the shoulder; 6 inches to the right of the middle line; 2.8 inches below the top of the shoulder.

WOUND NO. 4, BULLET NO. 3, (EXH. 18) continued

COURSE OF THE BULLET diagonal from the left, forward and downward to the left of the middle line into the aorta; tore the kidney artery; bruised and tore the front part of the left kidney; going to the left hip bone "where I found a slightly flattened bullet, the same being bullet No. 3, EXH 18

CAUSE OF BERARDELLI'S DEATH

Effects of wound NO. 4, from Bullet No. 3

Might have lived minutes, perhaps less than an hour.

NO REVOLVER FOUND IN EFFECTS OR CLOTHING.

Revolver not held in either case within minimum distance of ten inches. See testimony of

Slight bruising 1.8 inches below the inner edge of the eyebrow on the forehead and on the bridge of his nose.

WOUND NO. 4

At right shoulder practically but not exactly at right angle to shoulder.

DR. FREDERICK E. JONES

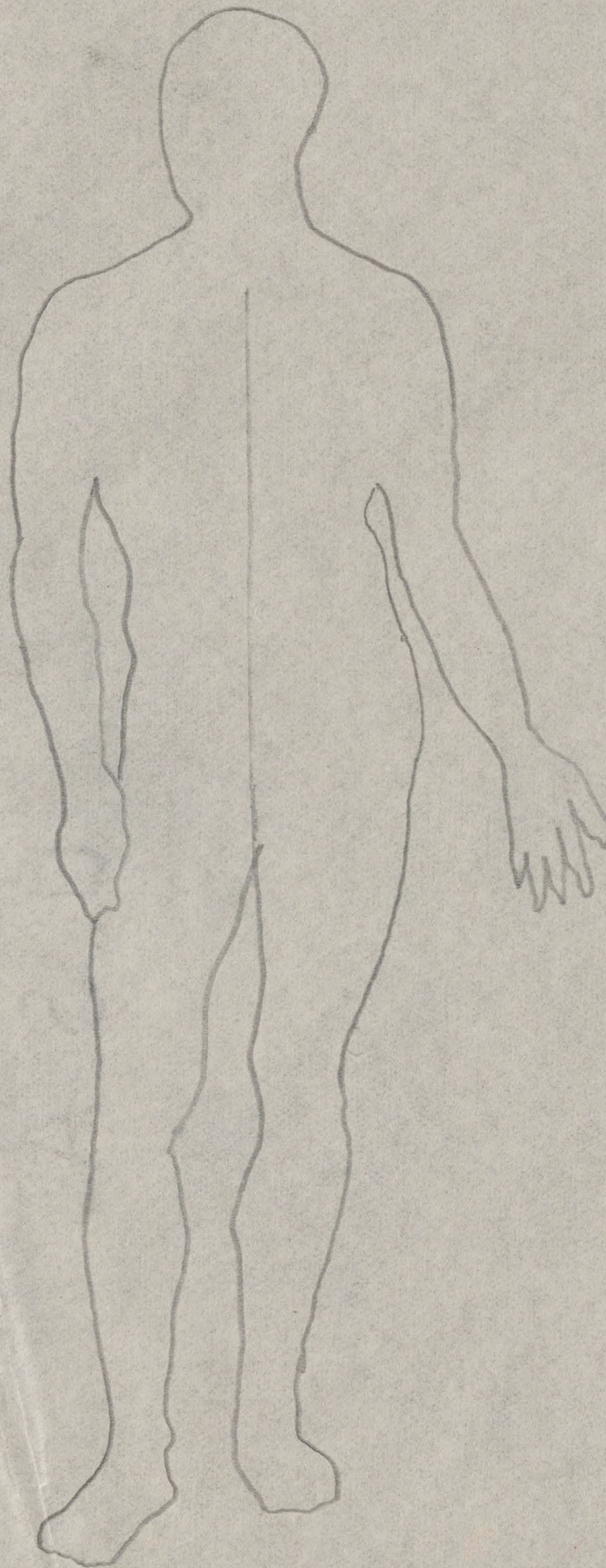
P. 15

FOUND EXH. 25, BEING BULLET NO. 5, identified it by two minute lines outside the casing about 1/2 back from the end. Figure "5" placed on base of the bullet at trial.

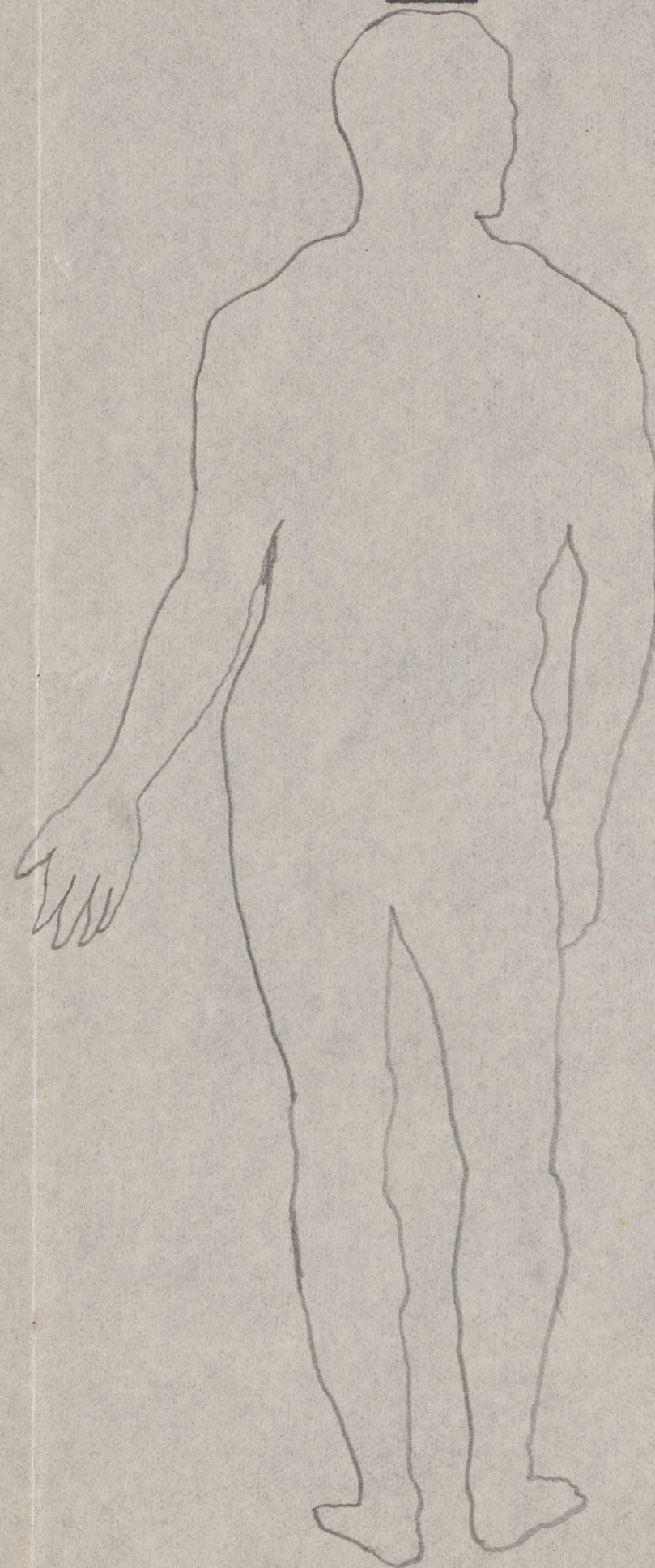FOUND BY NURSE in his presence about 7:45 A.M. of the 16th of April. Parmenter died at 5:00 o'clock that morning.

FREDERICK A. PARMENTER.

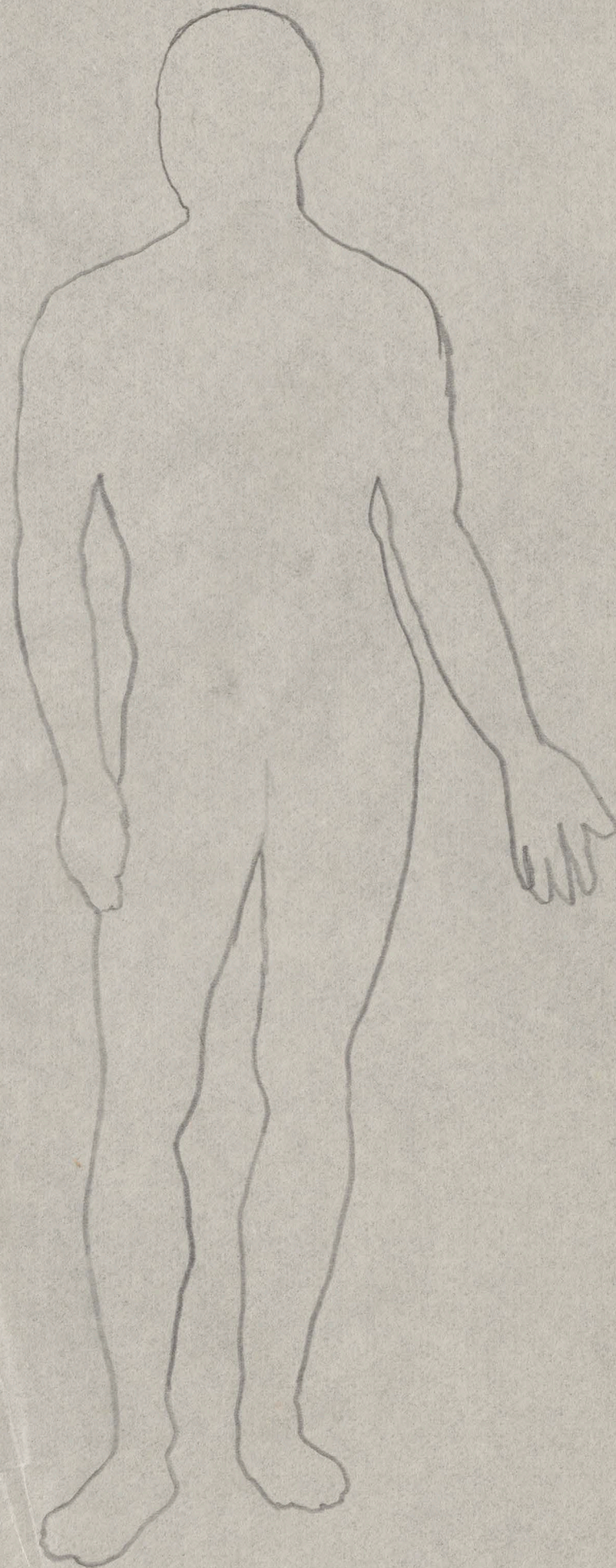
Front



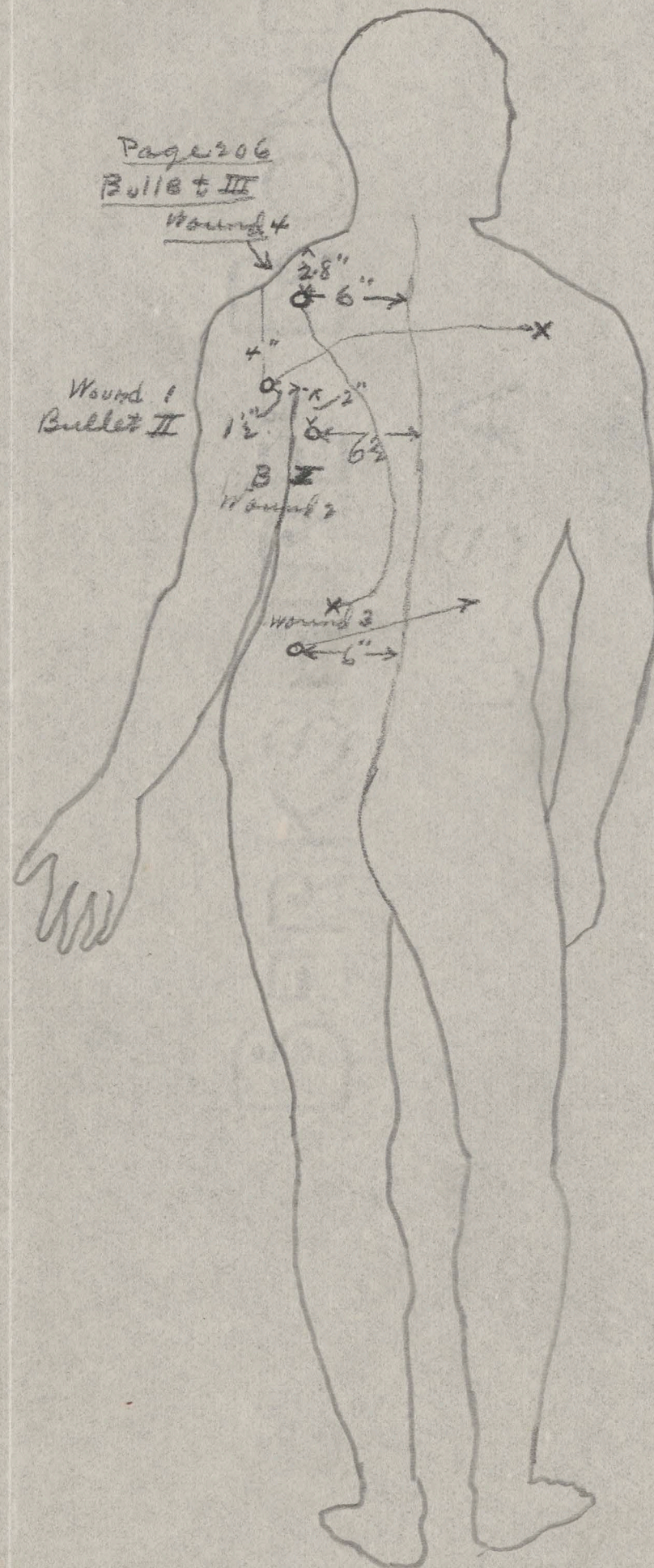
Back.



Front



Back.



Name, ALEXANDER BERARDELLI

(1)

Wound No. 1

Bullet wound of the Upper Arm, left, rear surface
with penetration of the
skin: subcutaneous tissues: deltoid and biceps muscles;
structures of the axilla: pectoralis minor muscle, left;
structures of the second intercostal space, left;
lung, left, upper lobe, with surrounding adhesions;
substernal tissues;
pleural cavity, right,
with lodgment therein against the
third rib, right, of the bullet

[No. 1 of entrance]

Associated:-

Ecchymosis of the axilla, left:
structures of the
second intercostal spaces, left and right:
pectoral muscles, left
Abrasion of the sternum, rear surface
Fracture of the third rib, right
Haemothorax, slight, left

[MADE BY BULLET No. II]

Name, ALEXANDER BERARDELLI

(2)

Wound No. 2

Bullet wound of the back, left side, upper,
with penetration of the
skin; subcutaneous tissues;
trapezius muscle
subcutaneous tissues of the flank, left;
pectoral muscles, left,
with lodgment therein of the bullet

[No. 2 of entrance]

Associated:-

Echymosis of the deep fascia and of the
subcutaneous tissues; skin of front of
chest, left side

[MADE BY BULLET No. 1]

Name, ALEXANDER BERARDELLI

(3)

Wound No. 3

Bullet wound of the back, left side, lower,
with penetration of the skin;
subcutaneous tissues;
gluteal muscle;
ilium; left;
iliacus muscle, deep fascia;
peritoneum of iliac fossa, left;
mesosigmoid; peritoneum of front wall, right;
rectus muscle, right,
with lodgment therein of the bullet

[No. 3 of entrance]

Associated: (possibly)

Wounds of the
meso-ileum (2)
ileum (4)
jejunum (1)
Haemoperitoneum (60 c.c.)

MADE BY BULLET No. IV]

Name, ALEXANDER BERARDELLI

(4)

Wound No. 4

Bullet wound of the back, right side, upper,
with penetration of the
skin; subcutaneous tissues; muscles of the back;
wall of the chest, right (fourth rib and intercostal space);
lung, right lower lobe, with surrounding adhesions;
Aorta, right and left walls
retroperitoneal structures, left side;
renal artery, left;
Kidney, left, lower pole;
peritoneum
peritoneal cavity;
intestine, small; meso-ileum; meso-sigmoid;
iliacus muscle, left,
with lodgment therein against the ilium, left,
of the bullet

[No. 4 of entrance]

Associated:-

Fracture of the fourth rib, right, lower edge
Haemothorax, left (slight); right (125 c.c.)
Haematoma of the peri-aortic and subpleural (parietal)
structures; diaphragm; retroperitoneal structures (prae-
nephric), left;
Haemoperitoneum (30 c.c.)
Haematuria

[MADE BY BULLET No. III]

Name, ALEXANDER BERARDELLI

(5)

Creases of the nose
Bruises, slight, of the forehead, left side
Chronic adhesive pleuritis, bilateral
Chronic perisplenitis, perihepatitis
Aneurismal pocket of the aorta, descending arch
Patency of the inguinal canal, left
Oedema of the lung, left, upper lobe (slight)
Ischaemia

Name, ALEXANDER BERARDELLI

WOUND No. 1 (Bullet No. II)

Position	Left upper arm, rear surface, 4 inches below top of shoulder, 1.5 inches from axillary fold
Structures traversed by bullet	Skin, subcutaneous fat, deltoid, biceps, pectoral muscles; second intercostal space, left: pleural cavity (obliterated by adhesions), left lung, upper lobe substernal tissues; rear surface of sternum right pleural cavity; third rib, right
Location of bullet	Right pleural cavity, under third rib in front, 3 inches from median line
Character of bullet	.22 caliber, full metal patch
Direction of path of bullet in body	Back to front, toward middle line, slightly downward, 45 degrees to right of sagittal plane, 20 degrees below horizontal plane
Effects of wound	Unimportant; slight bleeding into structures along its path
Proximity of weapon	Not close enough to burn or powder mark overcoat
Line of flight of bullet towards body	From behind and to the left

Name, ALEXANDER BERARDELLI

WOUND No. 2 (Bullet No. I)

Position	Left side of back, 6.5 inches to left of middle line, 2 inches below the level of the top of the axilla
Structures traversed by bullet	Skin; subcutaneous fat; muscles of the back and of left side of chest near the level of the fourth rib: pectoral muscles, left
Location of bullet	Pectoral muscles, left, deep surface, over upper border of fifth rib, near anterior axillary line
Character of bullet	.32 caliber full metal patch
Direction of path of bullet in body	Back to front, circling left side of chest, horizontal (Note: The edges of this wound and its non-penetrating character suggest oblique impact of the bullet)
Effects of wound	Unimportant
Proximity of weapon	Not close enough to burn or powder mark overcoat
Line of flight of bullet towards body	From behind

Name, ALEXANDER BERARDELLI

Wound No. 3 (Bullet No. IV)

Position	Left side of back, 3 inches to left of middle line, 1.5 inches below the crest of the ilium
Structures traversed by bullet	Skin; subcutaneous fat; gluteal muscle; ilium; left; iliacus muscle, left; mesosigmoid; peritoneal cavity; intestine, small ? peritoneum, front wall, right rectus muscle, right
Location of bullet	Rectus muscle, right, 3 inches from median line, 5 inches above brim of pelvis (front)
Character of bullet	.32 caliber, full metal patch
Direction of path of bullet in body	Back to front, toward middle line, and upward; 45 degrees to right of sagittal plane; 15 to 20 degrees above horizontal plane
Effect of wound	Not immediately important. Ultimately dangerous from possible peritonitis if perforations of small intestine were incidental to it
Proximity of weapon	Not close enough to burn or powder mark overcoat
Line of flight of bullet toward body	From behind and to the left, probably slightly upwards

Name, ALEXANDER BERARDELLI

WOUND No. 4.

(Bullet No. III)

Position	Back, right side (shoulder) 8 inches to right of middle line, 2.8 inches below the top of shoulder
Structures traversed by bullet	Skin, subcutaneous fat; muscles; wall of chest, right side; fourth rib and intercostal space, right in mid axillary line; pleural cavity, right; lung, right lower lobe, with surrounding adhesions; aorta, right hand wall close to the diaphragm, left hand wall 0.3 inch above the superior mesenteric artery; retroperitoneal structures, left side; renal artery, left; kidney, left, lower pole; peritoneum, lumbar region, left; meso-ileum; small intestine (five wounds present); mesosigmoid; iliacus muscle, left
Location of bullet	Left iliac fossa, in iliacus muscle, against the ilium, 0.6 inch below the crest, and 2.5 inches behind anterior superior spine.
Character of bullet	.32 caliber, full metal patch, slightly flattened on one side
Direction of path of bullet in body	Back to front, from right to left; from above downward, 50 degrees, approx., below the horizontal plane, 15 degrees, approx., in front of the coronal plane
Effect of wound	Necessarily fatal. Haemorrhage from right lung and from aorta into right chest and structures around aorta, and into peritoneal cavity
Proximity of weapon	Not close enough to burn or powder mark overcoat
Line of flight of bullet towards body	From above, behind, and to the right